

## Acoustic Trauma and Hyperbaric Oxygen Treatment

**Mesut MUTLUOGLU**

Department of Underwater and Hyperbaric Medicine  
Gulhane Military Medical Academy  
Haydarpaşa Teaching Hospital  
34668, Uskudar, Istanbul  
TURKEY

[Drmutluoglu@gmail.com](mailto:Drmutluoglu@gmail.com)

### **ABSTRACT**

*As stated in the conclusions of the HFM-192 report on hyperbaric oxygen therapy (HBOT) in military medical setting, acoustic trauma is a frequent consequence of military activity in operation. Acoustic trauma refers to an acute hearing loss following a single sudden and very intense noise exposure. It differs from chronic noise induced hearing (NIHL) loss in that it is usually unilateral and causes sudden profound hearing loss. Acoustic trauma is a type of sensorineural hearing loss affecting inner ear structures; particularly the inner and outer hair cells of the organ of Corti within the cochlea. Exposure to noise levels above 85 decibel (dB) may cause hearing loss. While long-term exposure to repetitive or continuous noise above 85 dB may cause chronic NIHL, a single exposure above 130-140 dB, as observed in acoustic trauma, may cause acute NIHL. The loudest sound a human ear may tolerate without pain varies individually, but is usually around 120dB. Military personnel are especially at increased risk for acoustic trauma due to fire arm use in the battle zone. While a machine gun generates around 145dB sound, a rifle generates 157-163dB, a 105 mm towed howitzer 183dB and an improvised explosive device around 180dB sound.*

*Acoustic trauma displays a gradually down-sloping pattern in the audiogram, particularly after 3000Hz and is therefore described as high-frequency hearing loss. Tinnitus is almost always associated with acoustic trauma. Feeling of fullness in ear and pain are other common symptoms. Tinnitus may significantly impair quality of life by interfering with concentration, attention or sleep and eventually causing anxiety and depression. Various established treatment modalities for tinnitus did not prove satisfactory outcomes.*

*HBOT improves oxygenation of the cochlea and the organ of Corti which are dependent solely on oxygen diffusion. Additionally, it reduces endothelial edema through vasoconstriction and reduced vascular permeability. Moreover, it improves hemorheology by reducing haematocrit, inhibiting platelet aggregation and improving erythrocyte flexibility. Experimental research demonstrated that HBOT reduces the amount of damage caused by acoustic trauma and clinical studies revealed significant hearing improvement in patients treated with HBOT.*

*As was concluded on the HFM-192 report on hyperbaric oxygen therapy (HBO) in military medical setting, HBO must be seen as part of a therapeutic continuum, without any interruption of the chain of treatment and HBOT in patients with acoustic trauma should preferably be administered at the acute phase.*

### **1.0 INTRODUCTION**

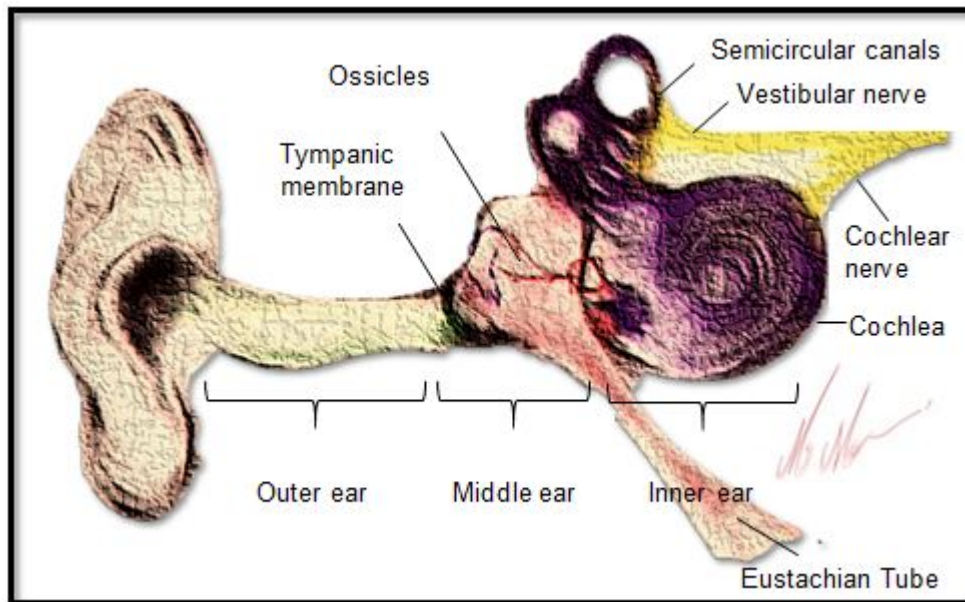
As stated in the conclusions of the HFM-192 report on hyperbaric oxygen therapy (HBO) in military medical setting, acoustic trauma is a frequent consequence of military activity in operation. Acoustic trauma refers to an acute hearing loss following a single sudden and very intense noise exposure. It differs from chronic noise induced hearing (NIHL) loss in that it is usually unilateral and causes sudden profound hearing loss. Acoustic trauma is a type of sensorineural hearing loss affecting inner ear structures; particularly the inner

## Acoustic Trauma and Hyperbaric Oxygen Treatment

and outer hair cells of the organ of Corti within the cochlea.

Hearing loss may be central or peripheral. While central hearing loss refers to damage involving the brain stem or auditory cortex, peripheral hearing loss is caused by pathologies involving the outer, middle or inner ear. Accordingly if hearing loss is related to pathologies involving the outer or middle ear structures it is described as conductive hearing loss, and if it involves the inner ear is defined as sensori-neural hearing loss.

Sound vibrations are collected in the outer ear, conducted through the middle-ear and finally converted to electrical signals and neural impulses within the inner ear (Figure 1).



**Figure 1: Collection, conduction and conversion of vibrations through the outer, middle and inner ear, respectively. The pinna collects sound waves which travel along the external auditory meatus up to the tympanic membrane. The mechanical displacement of the tympanic membrane affects directly the malleus in the middle ear which in turn conducts the sound waves to the incus and stapes, respectively. Next, the sound waves are conducted from the middle ear to the inner ear through the stapes and the oval window where they are transmitted within the perilymph along the scala vestibuli, the helicotrema, and the scala tympani. During this course the movement of the perilymph is transmitted to the basilar membrane within the organ of Corti where finally the inner and outer hair cells receive the sound waves and transform them into electrical signals. The depolarization of hair cells triggers an afferent impulse within the spiral ganglion cells in the modiolus and is eventually transmitted to the auditory cortex.**

While sensorineural hearing loss may affect either the cochlea or the auditory nerve, acoustic trauma is restricted to the inner and outer hair cells of the organ of Corti within the cochlea. Acoustic trauma differs from chronic noise induced hearing loss in that it is usually unilateral and causes sudden profound hearing loss. A brief comparison of acute and chronic noise-induced hearing loss is presented in table 1.

**Table 1: Comparison of acute and chronic noise-induced hearing loss**

Type of NIHL	Acute	Chronic
Duration of exposure	Brief	Long
Intensity of noise	Very intense	Intense
Severity of hearing loss	Profound	Moderate to severe
Unilateral/bilateral	Unilateral	Bilateral
Configuration of hearing loss	Down-sloping	Noise-notch
Affected frequencies	Broad-range	3000-6000Hz

Military personnel are especially at increased risk for acoustic trauma due to fire arm use in the battle zone. While a machine gun generates around 145 decibel (dB) sound, a rifle generates 157-163dB, a 105 mm towed howitzer 183dB and an improvised explosive device around 180dB sound (1). Examples of noise levels are presented in table 2.

**Table 2: Examples of noise levels.**

Noise level	Example
Up to 20 dB	Tickling clock, whispered voice
40 dB	Living room
50-60 dB	Normal conversation
70 dB	Hair dryer, Busy office
80-85 dB	City traffic, Motor bike
90 dB	Chainsaw, Noisy workplace
100dB	Construction site
110dB	Rock concert
130 dB	Heavy industry
140dB	Jet take-off
145 dB	Machine gun

## Acoustic Trauma and Hyperbaric Oxygen Treatment

155 dB	Rifle
180 dB	Improvised explosive device
183 dB	105 mm towed howitzer

Exposure to noise levels above 85 dB may cause hearing loss. While long-term exposure to repetitive or continuous noise above 85 dB may cause chronic NIHL, a single exposure above 130-140 dB, as observed in acoustic trauma, may cause acute NIHL. The loudest sound a human ear may tolerate without pain displays individual susceptibility, but is usually around 120dB (1).

Recommended limits for the prevention of NIHL for several sound levels are presented in table 3.

**Table 3: Permissible exposure duration for several noise levels**

Noise level	Permissible exposure duration
85 dB	8 hours
94 dB	1 hour
103 dB	7.5 minutes
109 dB	2 minutes
115 dB	30 seconds

Acoustic trauma usually does not affect the speech frequencies but the high frequencies of hearing. An audiogram is a diagnostic tool used to determine the severity and type of hearing loss. The configuration of an audiogram provides significant clues for both the etiology and prognosis of hearing loss. For instance the pattern of acoustic trauma induced hearing loss is typically characterized as a down-sloping audiogram (Figure 1).

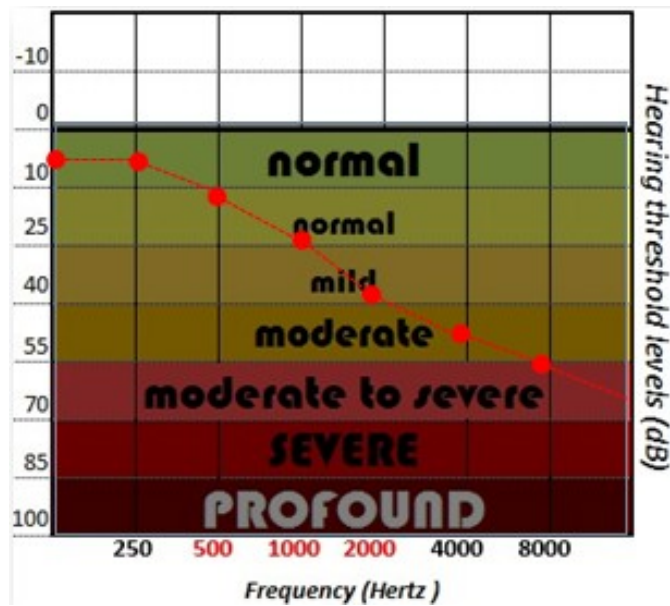


Figure 2: Typical down-sloping audiogram showing acoustic trauma.

## 2.0 EPIDEMIOLOGY

Military personnel are especially at increased risk for acoustic trauma due to fire arm use in the battle zone. Among post-deployment soldiers from Iraq and Afghanistan almost 1 in 3 reported exposure to acute acoustic blast trauma and of those 72% reported hearing loss (2). Fifty percent of soldiers exposed to explosives, particularly to improvised explosive devices, in operation Iraqi & Afghanistan reported tinnitus (2).

## 3.0 PATHOPHYSIOLOGY

The pathophysiology of acoustic trauma involves principally damage to sensory cells of organ of Corti, i.e. the inner (IHC) and outer hair cells (OHC) (Figure 3-4-5). Repetitive or continuous sharp noise may also affect the supportive cells of the organ of Corti. While low frequency sounds may damage both IHC and OHC, high frequency sounds damage only hair cells at the basal end (3, 4). Very intense noise exposure may also lead to the separation of the stereocilia from the tectorial membrane, may alter mitochondrial function and may lead to swelling and structural damage of the dendrites. Acoustic trauma additionally causes endothelial edema and impairs perfusion due to the closure of endarteries. Persisting edema further causes the transition of hair cells into non-functional endothelial cells.

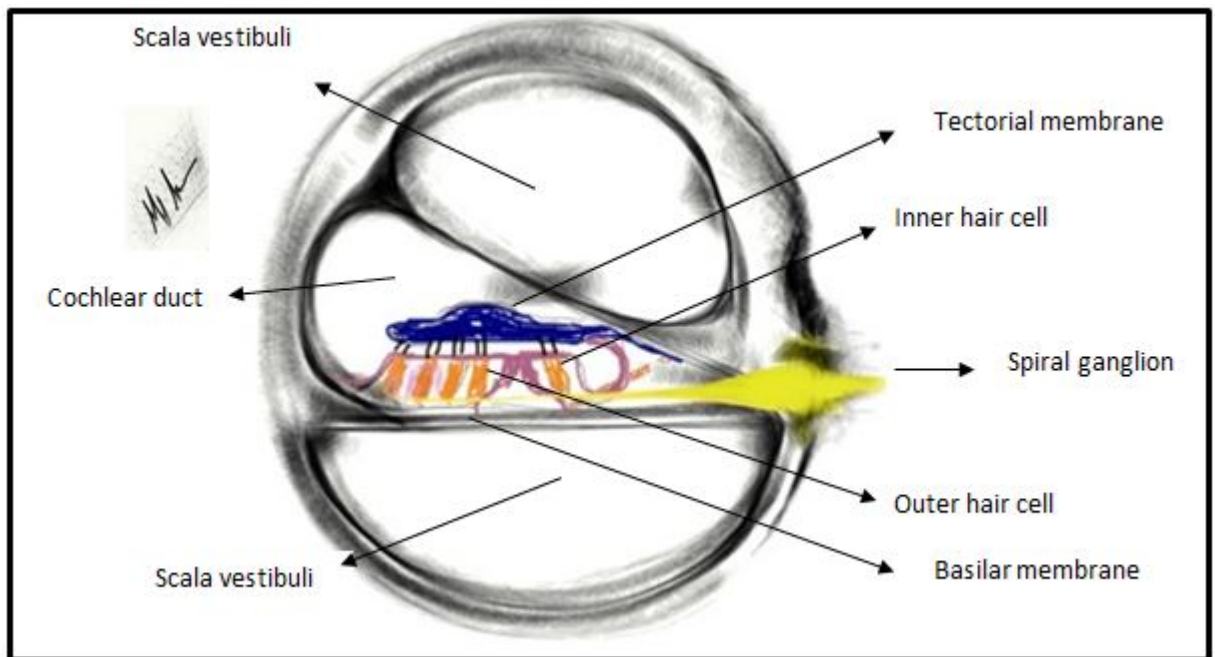


Figure 3: The organ of Corti.

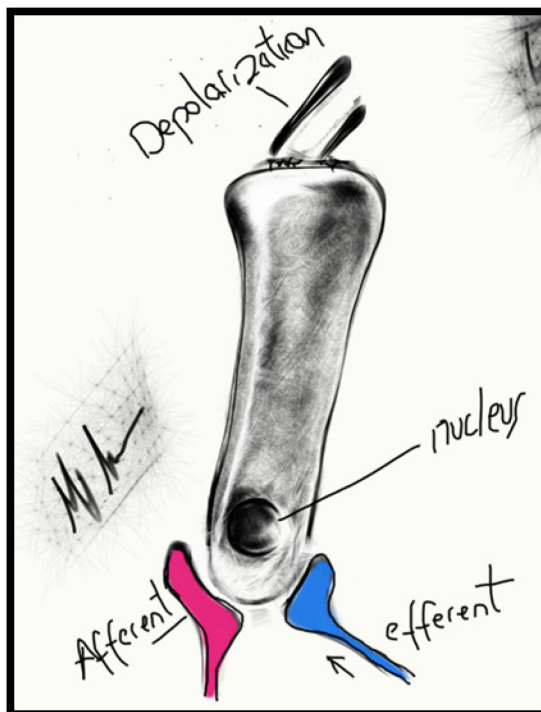


Figure 4: Outer hair cell.

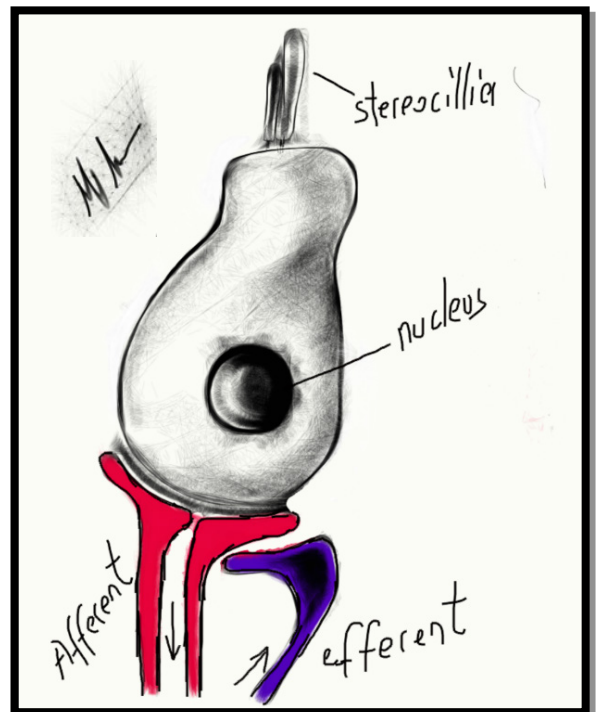


Figure 5: Inner hair cell.



## **4.0 CLINICAL MANIFESTATIONS**

Tinnitus is almost always associated with acoustic trauma. It is described as a subjective perception of sound in the absence of external sounds. Patients describe this sound as a ringing, roaring or buzzing sensation. Tinnitus may significantly impair quality of life by interfering with concentration, attention or sleep and eventually causing anxiety and depression. Tinnitus is not specific to acoustic trauma and should be differentiated from other potential causes.

Differential diagnosis of tinnitus:

- i. Presbycusis*
- ii. Head injury*
- iii. Meniere's disease*
- iv. Otosclerosis*
- v. Otitis media*
- vi. Meningitis*
- vii. Acoustic trauma*

Feeling of fullness in ear, pain and hearing loss are other common sign and symptoms associated with acoustic trauma. Hearing loss has several important military implications. It may lead to the disqualification or loss of qualified officers. It may decrease productivity and also increase medical expenses related to the treatment. In the battle field, the hearing impaired may miss the targets, may misunderstand and misinterpret commands and thereby endanger the safety of crew members.

## **5.0 DIAGNOSIS**

The diagnosis of acoustic trauma is initially established by an audiogram and tympanogram. Computerized tomography and magnetic resonance imaging of the temporal bone are used for differential diagnosis. An audiogram shows hearing threshold levels of patients for pre-determined frequencies in dB. In a typical audiogram the red color denotes the right ear and the blue color the left. Several signs are also used to distinguish conductive from sensorineural hearing loss (Figure 6-7).

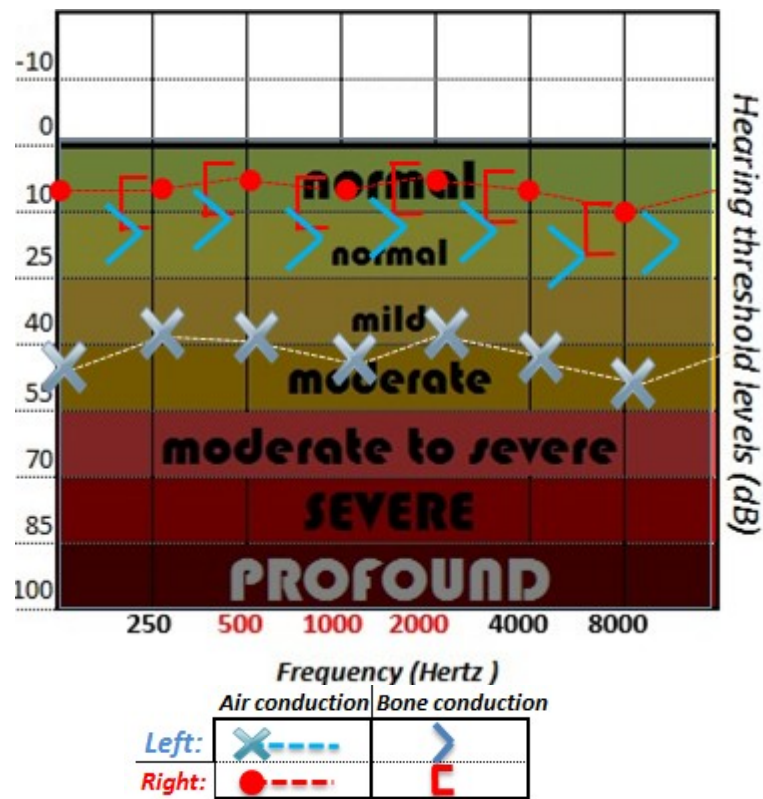


Figure 6: Typical audiogram showing conductive hearing loss in the left ear (blue cross) and normal hearing thresholds in the right ear (red color). Red color in audiograms represents the right ear and blue color the left ear.

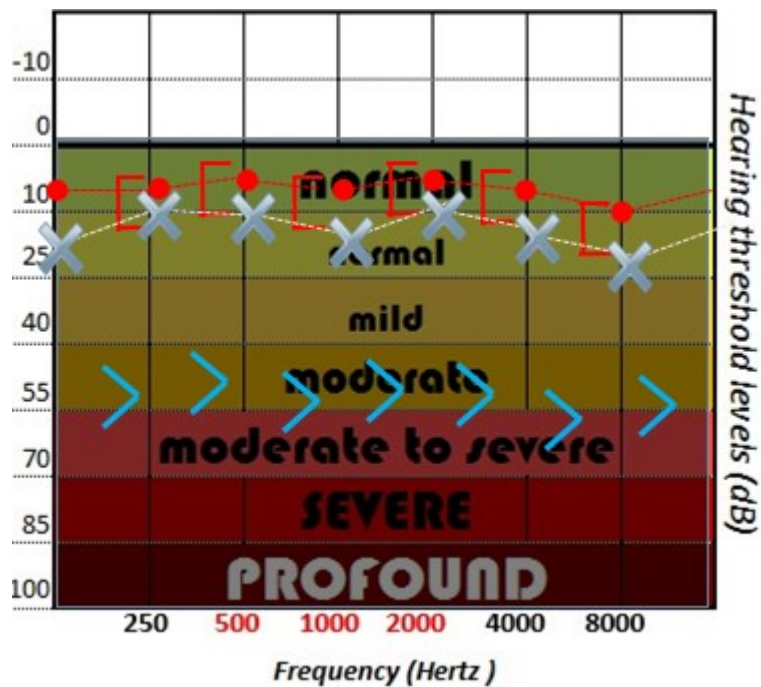


Figure 7: Typical audiogram showing sensori-neural hearing loss in the left ear (blue arrowhead) and normal hearing thresholds in the right ear (red color).



## **6.0 TREATMENT**

The treatment of tinnitus is challenging. Although several therapeutic modalities have been used to date, none proved efficient alone or together.

Treatment options for tinnitus

- i. Vasodilators*
- ii. Vitamins*
- iii. Anticoagulants*
- iv. Heparin*
- v. Tranquilizers*
- vi. Diuretics*
- vii. Volume expanders*
- viii. Carbogen inhalation*
- ix. Steroids (Systemic or intratympanic)*
- x. Hyperbaric oxygen therapy*

Intratympanic steroids, which are administered through the middle ear round window membrane, target directly the inner ear structures, and thereby achieve higher concentration at the end organ as compared with systemic steroids. Compared with systemic steroids they have lower complication rates due to very little systemic absorption, and therefore may be used in cases where systemic steroids are contraindicated. Additionally they have the advantage of being administered on an outpatient basis. On the other hand intratympanic steroid administration is an invasive and demanding procedure and may lead to complications such as bleeding.

### **6.1 Hyperbaric oxygen treatment**

The European Underwater and Baromedical Society accepted sensorineural hearing loss as an indication for HBO following a consensus opinion of experts. Tinnitus, on the other hand, was not accepted and was classified as level E: No evidence of beneficial action, or methodological or interpretation bias preclude any conclusion. Similarly the Undersea and Hyperbaric Medical Society has accepted SSNHL as an indication for HBO in 2011.

Hyperbaric oxygen therapy (HBOT) improves oxygenation of the cochlea and organ of Corti which are dependent solely on oxygen diffusion. Additionally, it reduces endothelial edema through vasoconstriction and reduced vascular permeability. Moreover, it improves hemorheology by reducing haematocrit, inhibiting platelet aggregation and improving erythrocyte flexibility.

Experimental research demonstrated that HBOT reduces the amount of cochlear damage. In an experimental study performed on guinea pigs the effects of HBOT on acoustic trauma was assessed by brainstem auditory

evoked potential (BAEP) and distortion product otoacoustic emission (DPOAE). The cochleae were analysed using scanning electron microscopy (SEM). Researchers found a significant difference in the signal-to-noise ratio of the DPOAE amplitudes for the 1- to 4-kHz frequencies. Additionally, SEM findings revealed that damaged outer hair cells (OHC) due to acoustic trauma displayed significant recovery following HBOT ( $p = 0.0159$ ). This finding was further confirmed using the DPOAE (5).

In an acoustic trauma model established on guinea pigs, the effects of several treatment modalities such as intravenous infusion of isotonic saline (placebo); blood flow promoting drugs (hydroxyethyl starch = HES, pentoxifylline, betahistine, ginkgo biloba, naftidrofuryl); antiinflammatory agents (prednisolone, diclofenac sodium, histamine H1-receptor antagonist); isobaric oxygenation (IBO); and hyperbaric oxygenation (HBO) with and without supplements (simultaneous infusion of isotonic saline, pentoxifylline, prednisolone, or HES) were assessed using cochlear blood flow (CoBF), perilymphatic partial pressure of oxygen (PL-pO<sub>2</sub>), cochlear microphonics (CMs), compound action potentials of the auditory nerve (CAPs), and auditory brainstem responses (ABRs). HBOT (60 min) 60 min was administered after cessation of noise. None of the treatment modalities, except for IBO and HBOT, proved beneficial either alone or combination. A sustained therapeutic effect on noise-induced cochlear ischemia was achieved only by HES, HBO + HES, and pentoxifylline. The best therapeutic effect on noise-induced hearing loss was achieved with HBO and prednisolone together (6).

The majority of clinical studies revealed significant hearing improvement in patients treated with HBOT. Pilgramm et al. demonstrated that HBO significantly shortened the course of healing with respect to high-pitch perception dysacusis (7). A literature survey conducted by Lamm K, who found that 65% of patients treated with HBOT demonstrated hearing improvement, revealed the importance of timing in the treatment of acoustic trauma by HBOT. Accordingly, if HBO had started from 2 to 6 weeks after the diagnosis of acoustic trauma, one half of the cases showed a marked hearing gain and one-third a moderate improvement. Additionally, 4% of patients reported that they no longer experienced tinnitus and 81% expressed a significant decrease. However, if HBO was administered at a later stage, but still within 3 months following a trauma, recovery rates decreased significantly, e.g. only 13% of patients showed a definite improvement in hearing and 25% a moderate improvement. 7% of patients no longer suffered from tinnitus and 44% reported an intensity decrease. If HBO was started after 3 months of initial exposure, hearing improvement was found unlikely. Of note, in the majority of patients with no hearing improvement, HBO was administered following unsuccessful conventional therapy (8).

In a study performed on 68 soldiers diagnosed with acoustic trauma, patients were treated with one of the three different regimens. Group 1 received oral medication only. Group 2 received HBOT twice a day for 3 days then once a day (7 days), combined with intravenous medication (5 days) followed by oral treatment. Group 3 received HBOT once a day and oral medication for 10 days. Medical treatment consisted of methylprednisolone and piracetam in all groups. Average Hearing Gain (AHG) and Average Residual Hearing Loss (ARHL) were calculated using audiometry at day 10. The mean AHG and mean ARHL results demonstrated a significant benefit for the combination of HBO and medical therapy over medical treatment alone (9).

Yikovski et al., in a study conducted on 120 ears compared the recovery from hearing impairment and tinnitus in patients who received HBOT and who did not. The HBOT was given daily for 1-8 days. The average recovery of hearing both at high and speech frequencies was significantly better and tinnitus persisted less commonly in the HBOT group. The rate of normal hearing recovery at the end of the follow-up period was significantly higher in the HBOT group than in the NBOT group (10).

As was concluded on the HFM-192 report on HBO in military medical setting, HBO must be seen as part of a therapeutic continuum, without any interruption of the chain of treatment and HBOT in patients with acoustic trauma should preferably be administered at the acute phase.

## 7.0 REFERENCES

1. Baldwin TM: Tinnitus, a military epidemic: is hyperbaric oxygen therapy the answer? *J. Spec. Oper. Med.* 2009, 9: 33-43.
2. <http://www.guardian.co.uk/uk/2009/dec/20/afghan-veterans-hearing-damage>. Townsend M.: Two-thirds of Afghan war veterans are suffering from hearing damage. The intense noise of the battlefield is afflicting British troops. *The Observer* 2009, 20 Dec.
3. Nakashima T1, Yanagita N. Outcome of sudden deafness with and without vertigo. *Laryngoscope.* 1993 Oct;103(10):1145-9.
4. Kojima Y1, Ito S, Furuya N. Hearing improvement after therapy for hyperlipidemia in patients with chronic-phase sudden deafness. *Ann Otol Rhinol Laryngol.* 2001 Feb;110(2):105-8.
5. Colombari GC, Rossato M, Feres O, Hyppolito MA: Effects of hyperbaric oxygen treatment on auditory hair cells after acute noise damage. *Eur. Arch. Otorhinolaryngol.* 2011, 268: 49-56.
6. Lamm K, Arnold W: Successful treatment of noise-induced cochlear ischemia, hypoxia, and hearing loss. *Ann. N. Y. Acad. Sci.* 1991, 884: 233-248.
7. Pilgramm M, Schumann K: Hyperbaric oxygen therapy for acute acoustic trauma. *Arch. Otorhinolaryngol.* 1985, 241: 247-257.
8. Lamm K, Lamm H, Arnold W: Effect of hyperbaric oxygen therapy in comparison to conventional or placebo therapy or no treatment in idiopathic sudden hearing loss, acoustic trauma, noise-induced hearing loss and tinnitus. A literature survey. *Adv. Otorhinolaryngol.* 1998, 54: 86-99.
9. Lafere P, Vanhoutte D and Germonpre P: Hyperbaric oxygen therapy for acute noise-induced hearing loss: evaluation of different treatment regimens. *Diving and Hyperbaric Medicine.* 2010; 40:63-7.
10. Ylikoski J, Mrena R, Makitie A, Kuokkanen J, Pirvola U, Savolainen S: Hyperbaric oxygen therapy seems to enhance recovery from acute acoustic trauma. *Acta Otolaryngol.* 2008, 128: 1110-1115.

